

# **Outcome of modified Keller interposition arthroplasty in management of hallux rigidus**

**Mamdouh Mohammed Alkaramany M.D**

Orthopaedic Department, Faculty of Medicine, Benha University, Benha, Egypt

Correspondence to **Mamdouh Mohammed AL Karamany**, MD, Ass. professor orthopaedic surgery. **Orthopedic department, Benha University El-Shaheed Farid Nada street, Benha, Qalyubia, Egypt,**

Tel: 01227323479;

e-mail: **mhmedsharaf@yahoo.com**

## **Abstract**

**Study design:** prospective study.

**Background:** The controversy about the treatment of hallux rigidus exist in the high grades of the disease. Arthrodesis of the first MTP joint which is the main stay treatment of advanced hallux rigidus has its own problems and limitations Mroczek and Miller described their modification of the original Keller procedure, which consisted of an oblique resection of the articular surface of the phalanx, thereby maintaining the plantar plate attachment to the proximal phalanx and avoid shortening of the first ray. The purpose of the study was to assess the results of modified Keller capsular interposition arthroplasty in management of hallux rigidus.

**Patients and methods:** Between December 2014 and June 2016, a prospective study was conducted involving twenty patients who underwent modified oblique Keller capsular interpositional arthroplasty for hallux rigidus. Inclusion criteria of the study included patients with hallux rigidus grade 3 and 4 according to Coughlin and Shurans classification, after failure of conservative treatment for at least 6 weeks. Exclusion criteria included Patients with systemic inflammatory diseases (rheumatoid arthritis, systemic lupus erythematosus), patients with trophic ulcer or impaired sensation, previous surgery or fractures in the hallux, together with patients who refused to join the study

**Results:** The average follow-up period was 22.16 months (range, 12 to 36). At final follow-up, average postoperative VAS for pain improved significantly from  $5.65 \pm 1.09$  to  $1.5 \pm 1.1$  ( $p < 0.00001$ ). The average postoperative active dorsiflexion range improved significantly from  $10.85 \pm 3.25$  to  $22.85 \pm 4.96$  ( $P < 0.001$ ). The average postoperative AOFAS score improved from  $57.85 \pm 9.24$  points preoperatively to  $89.2 \pm 4.8$  ( $P < 0.001$ ).

**Conclusion:** The simple and cheap technique used in the current case series, presented modified oblique Keller interposition arthroplasty as a treatment modality for advanced hallux rigidus with overall favorable outcome results and low complications.

**Keywords:** Hallux regidus, interposition arthroplasty, modified Killer arthroplasty.

## Introduction

The term “hallux rigidus” described an osteoarthritis of the first toe metatarsophalangeal (MTP) joint. This condition was first reported in 1887 by Davies-Colley who used the name “hallux flexus” [1]. Few years later, Cotterill was the first to use the term “hallux rigidus” [2]. Since then many eponyms have been used to describe the disease, such as dorsal bunion, hallux malleus, metatarsus primus elevates [3].

It is more common in females, over the age of 60 years, with incidence of about 2% of the population. Patients usually present with arthralgia that usually worsened by walking. With time the first MTP joint enlarges and the symptoms become more pronounced with decreased range of motion of the hallux, especially dorsiflexion [4].

Beeson et al (2008), conducted a systematic review of the literature to evaluate the different hallux rigidus classification systems [5]. They conclude that the classification system of Coughlin and Shurnes to be the closest to a “gold standard”. These authors classified Hallux rigidus into four grades according to clinical subjective (pain), objective (range) and radiographic findings (osteophytes) [6].

Non-operative treatment yield good results in early stages. Non-steroidal anti-inflammatory drugs, intra-articular injections and physiotherapy with or without sesamoid mobilization were tried [7]. Operative management were indicated in cases of failed conservative treatment. surgical options choice should be determined based primarily on the severity of the disease. For early stages cheilectomy is recommended, while for late stages options include various arthroplasty and arthrodesis procedures [8].

While arthrodesis offers better early clinical outcomes, it has many limitations including prolonged weight bearing restrictions postoperatively and activity limitations as well as high complications with non-union reported in 10% of cases [9]. Implant arthroplasty using either metal or silicon implant has been associated with high complication rates from synovitis to implant related problems (loosening and fractures) and is not recommended by many foot and ankle surgeons [10].

The modified oblique Keller resection arthroplasty combined by dorsal cheilectomy and dorsal capsular interposition arthroplasty described by Mroczek and Miller [11] is an attractive option offering pain relief without sacrificing range of motion. However, the technique hasn't got popularity. The aim of the current study was to assess the outcome of Modified oblique Keller capsular interposition arthroplasty in treatment of late stages hallux rigidus.

## **Patients and methods**

In the period between December 2014 and June 2016, a prospective study was conducted involving twenty patients who underwent modified oblique Keller capsular interpositional arthroplasty for hallux rigidus.

Inclusion criteria of the study included patients with hallux rigidus grade 3 and 4 according to Coughlin and Shurans classification, after failure of conservative treatment for at least 6 weeks. All patient described themselves as independent, active and were seeking treatment to maintain their quality of life.

Exclusion criteria included Patients with systemic inflammatory diseases (rheumatoid arthritis, systemic lupus erythematosus), patients with trophic ulcer or impaired sensation, previous surgery or fractures in the hallux, together with patients who refused to join the study. There were no selection limitations for age and sex. All patients had signed informed consent, and the study protocol was approved by ethical committee of Benha university.

There were 4 males and 16 females with mean age of 59.25 years (range, 49 to 70). The average duration of symptoms before surgery was 18.9 months (range, 8 to 36). Eight patients were grade 3 and the rest was grade 4. Eight operations were performed on the left hallux and 12 on the right.

### **Preoperative assessment**

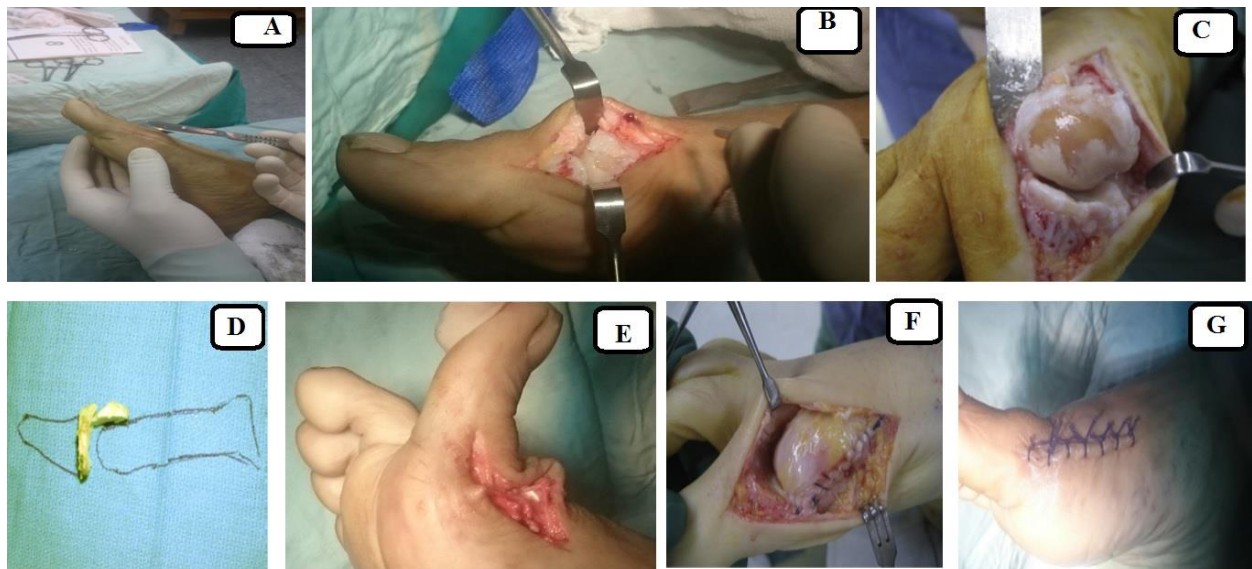
Detailed history and physical examination were conducted preoperatively with emphasis on the degree of pain as measured by visual analogue scale VAS, range of movement of the first MTP joint as measured by goniometer. Preoperative Modified American orthopedic foot and ankle society (AOFAS) score were then completed. Radiographic examination included weight bearing anteroposterior (AP), lateral, and axial views.

### **Surgical technique:**

All operations were done under spinal anesthesia with the use of a pneumatic tourniquet. Patients were positioned supine. A dorsal medial longitudinal incision extends from the middle of the first metatarsal to the middle of the proximal phalanx (fig1). Care was taken not to injury the dorsal-medial cutaneous nerve of the hallux.

The deep fascia was incised and the capsule of the first TM joint was opened. A curved bone lever was then used to release any first metatarsal - sesamoidal adhesions. With use of a saw, a dorsal cheilectomy of the metatarsal head osteophytes and wedge shaped osteotomy of the proximal phalanx was done by an oscillating saw with care taken to preserve the insertion of short flexors on the planter aspect of the base of the proximal phalanx of big toe.

Intra-operative movement of proximal phalanx over the first metatarsal was checked to ensure at least 80 degree of dorsiflexion. The dorsal capsule was advanced over the metatarsal head and was sutured into the planter plate with the use of a small curved needle acting as capsular interposition arthroplasty. The wound was closed in layers then dressed with compression bandage.



**Fig1: Intraoperative photograph demonstrating surgical technique**

A: medial skin incision, B: exposure of the 1st MTP joint

C: arthritic changes in the 1st MTP joint, D: illustration of the resected

bone.

E: dorsiflexion range of big toe, F:interposition of dorsal capsule

G: skin closure

### **Post-operative follow-up**

A stiff solid shoe was used for protected ambulation in the early postoperative 3 weeks. Each patient was advised to perform first metatarsophalangeal range of motion exercises daily for the postoperative 3 months. Weight bearing was allowed as tolerated.

## **Results**

The average follow-up period was 22.16 months (range, 12 to 36). At final follow-up, average postoperative VAS for pain improved significantly from  $5.65 \pm 1.09$  to  $1.5 \pm 1.1$  ( $p < 0.00001$ ). The average postoperative active dorsiflexion range improved significantly from  $10.85 \pm 3.25$  to  $22.85 \pm 4.96$  ( $P < 0.001$ ). The average postoperative AOFAS score improved from  $57.85 \pm 9.24$  points preoperatively to  $89.2 \pm 4.8$  ( $P < 0.001$ ).

Superficial skin infection occurred in two patients, which was improved with daily dressing and parenteral antibiotic for 3 days. Neuropraxia of the dorsal-medial cutaneous nerve of the great toe occurred in one patient. The patient complained from burning pain which was improved after 8 weeks with neurotonic medications.

The possible other complications as metatarsalgia, postoperative stiffness, EHL injury and FHL injury were not reported in the current study.

## **Discussion**

Controversy still exist about the treatment of high grades hallux rigidus. Arthrodesis of the first MTP joint which is the main stay treatment of advanced hallux rigidus has its own problems and limitations. Loss of motion and exertional pain is not favored by a lot of patients apart from the delay in return to daily activities for at least 2 or 3 months till complete union of the arthrodesis [9].

Furthermore, the complications which accompanied implant arthroplasty of the first MTP joint together with technical difficulties and high costs make this treatment modality not popular. Keller resection arthroplasty with removal of only the proximal one-fourth of the proximal phalanx and detachment of the plantar plate from the base of the proximal phalanx offered an alternative simple procedure with improvement of range of motion. Metatarsalgia however developed in many patients due to shortening of the first ray. Mroczek and Miller described a modification of the Keller resection arthroplasty procedure, which consisted of wedge resection of the head of the proximal phalanx, thereby maintaining the attachment of the plantar plate to the proximal phalanx and avoid shortening of the first ray [11].

The current study showed the results of modified oblique Keller interposition arthroplasty as a treatment modality which avoid replacement arthroplasty complications and arthrodesis limitations. The procedure should be considered as a joint reconstructive procedure, because it preserves the first MTP joint range of motion without shortening the first ray. The study included 20



patients with advanced hallux rigidus (8 grade 3 and 12 grade 4). At final follow up, significant improvement in pain VAS, dorsiflexion range, and AOFAS score was achieved in all patients.

Various interpositional arthroplasties with either allografts [12] (regenerative tissue matrix, consisting of collagen and extracellular protein matrices created from human cadaver tissue) or autograft (dorsal capsular [11,13], medial capsular [14], extensor hallucis longus [15], free plantaris [16] or gracilis tendons [6,17]) have been described. All have shown increase in range of motion (table 1) as well as outcome score (table2) comparable to those obtained in the current study.

**Table (1): comparison of range of motion outcome between the present study and 6 published capsular interpositional arthroplasty studies:**

Investigator	Year	Number of patients	Follow up in months	ROM measurement	Preoperative doriflexion	Postoperative dorsiflexion	Preoperative planter flexion	Post operative	Preoperative total ROM	Postoperative total ROM
Present study	2017	20	18	goniometer	10.85	27.9	34.05	33.9	38.75	67.95
Clews et al [14]	2015	34	45	goniometer	11.1	26.6	38.8	37.5	49.1	64.1
Kennedy et al [16]	2006	21	38	goniometer	-	-	-	-	33	54
Lau and	200	11	25.	unrepor	5.4	30.4	-	-	27	64

<b>Danials [17]</b>	<b>1</b>		<b>2</b>	<b>ted</b>						
<b>Hamilton [13]</b>	<b>1997</b>	<b>41</b>	<b>120</b>	<b>unreported</b>	<b>&lt; 10</b>	<b>50</b>	<b>-</b>	<b>-</b>	<b>47.2</b>	<b>66.5</b>

Table (2): comparison of AOFAS score outcome between the present study and 3 published capsular interpositional arthroplasty studies

<b>Investigator</b>	<b>Year</b>	<b>Number of patients</b>	<b>Follow up in months</b>	<b>Preoperative AOFAS score</b>	<b>Postoperative AOFAS score</b>
<b>Present study</b>	<b>2017</b>	<b>20</b>	<b>22.2</b>	<b>57.85</b>	<b>89.2</b>
<b>Clew study [14]</b>	<b>2015</b>	<b>34</b>	<b>45</b>	<b>50.8</b>	<b>89.6</b>
<b>Lau and Danials [17]</b>	<b>2001</b>	<b>11</b>	<b>25.2</b>	<b>37.5</b>	<b>77.3</b>
<b>Hamilton [13]</b>	<b>1997</b>	<b>41</b>	<b>120</b>	<b>58</b>	<b>83.1</b>

The complications reported in the current series were minor with 2 cases of superficial infection and a case of neuropraxia of the dorsomedial cutaneous nerve. The use of dorsal capsule as local flap avoids the donor site complications reported with free tendon grafts or the high costs of allografts.

## **Conclusion**

The simple and cheap technique used in the current case series, presented modified oblique Keller interposition arthroplasty as a treatment modality for

advanced hallux rigidus with overall favorable outcome results and low complications.

## References

1. Davies-Colley N. Contraction of the metatarsophalangeal joint of the great toe. *Br Med J.* 1887; 1:728.
- 2- Cotterill JM. Stiffness of the Great Toe in Adolescents. *Br Med J.* 1887; 1:1158.
- 3- Weinfeld SB, Schon LC. Hallux metatarsophalangeal arthritis. *Clin Orthop Relat Res.* 1998;(349):9–19.
- 4- Drago JJ, Oloff L, Jacobs AM. A comprehensive review of hallux limitus. *J Foot Surg.* 1984; 23:213–220.
- 5- Beeson P, Phillips C, Corr S, Ribbans W. Classification systems for hallux rigidus: a review of the literature. *Foot Ankle Int.* 2008; 29: 407-414.
- 6- Coughlin M, Shurnas P. Hallux rigidus: demographics, etiology, and radiographic assessment. *Foot Ankle Int.* 2003; 24:731-743.
- 7- Shamus J, Shamus E, Gugel RN, Brucker BS, Skaruppa C. The effect of sesamoid mobilization, flexor hallucis strengthening, and gait training on reducing pain and restoring function in individuals with hallux limitus: a clinical trial. *J Orthop Sports Phys Ther.* 2004 Jul; 34(7):368-376.
- 8- Keiserman L, Sammarco V, Sammarco G: Surgical treatment of the hallux rigidus. *Foot Ankle Clin.* 2005; 10(1):75-96.
- 9- Raikin S, Ahmad J, Pour A, Abidi N. Comparison of arthrodesis and metallic hemiarthroplasty of the hallux metatarsophalangeal joint. *J Bone Joint Surg Am.* 2007; 89(9):1979–1985.
- 10- Shereff MJ, Jahss MH. Complications of Silastic implant arthroplasty in the hallux. *Foot Ankle.* 1980; 1:95-101.

- 11- Mroczek KJ, Miller SD. The modified oblique Keller procedure: a technique for dorsal approach interposition arthroplasty sparing the flexor tendons. *Foot Ankle Int.* 2003; 24:521-522.
- 12- Berlet G, Hyer C, Lee T. Interpositional arthroplasty of the first MTP joint using a regenerative tissue matrix for the treatment of advanced hallux rigidus. *Foot Ankle Int.* 2008; 29(1):10-21.
- 13- Hamilton W, O'Malley M, Thompson F. Capsular interpositional arthroplasty for severe hallux rigidus. *Foot Ankle Int.* 1997; 18:68 – 71.
- 14- Clews CN, Kingsford AC, Samaras D. Autogenous capsular interpositional arthroplasty surgery for painful hallux rigidus: assessing changes in range of motion and postoperative foot health. *J Foot Ankle Surg.* 2015; 54(1):29-36.
- 15- Thordarson D, Hahn M, Gerhardt B: Medial capsular interpositional arthroplasty for severe hallux rigidus. *Foot Ankle Int.* 2009; 30(6):494 – 499.
- 16- Kennedy J, Chow F, Dines J, Gardner M, Bohne W. Outcomes after interposition arthroplasty for treatment of hallux rigidus. *Clin Orthop Relat Res.* 2006; 445:210-215.
- 17- Lau JT, Daniels TR. Outcomes following cheilectomy and interpositional arthroplasty in hallux rigidus. *Foot Ankle Int.* 2001; 22(6):462-470.